


March 19, 2015
Newport Beach, CA

ENT Procedures
Jose C. Mercado, PA-C, MMS, DFAAPA

Updated 01/24/2015

ENT Procedures Workshop



Clear Instruction Live Demonstration Hands-On Practice

Learn by doing

Removal Foreign Body (Nose)	Control Anterior Epistaxis
Control Posterior Epistaxis	Fine Needle Aspiration
Peritonsillar Abscess	Auricular Hematoma

Introduction

There are multiple methods and techniques available to successfully complete all the topics presented in this workshop. Some are based on patient request, available equipment or supervising physician's preference.

The goal of this workshop is to correctly demonstrate the most common methods and give participants time for hands on training.

ENT Procedures Workshop

Learning Objectives

- Discuss indications for and practice removal nasal foreign body.
- Discuss indications for and practice control anterior epistaxis.
- Discuss indications for and practice control posterior epistaxis.
- Discuss indications for and practice fine needle aspiration.
- Discuss indications for and practice peritonsillar abscess drainage.
- Discuss indications for drainage auricular hematoma and practice splinting.

Removal Foreign Body (Nose)

- Purulent unilateral nasal discharge, especially in children
- Usually lodge on the floor of anterior or middle third

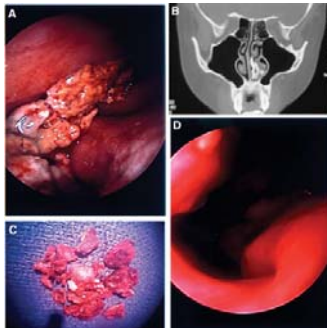


Figure. A: Fiberoptic nasal endoscopy shows the mass in the left anterior nasal cavity.
 B: Coronal CT shows the area of attenuation in the left inferior turbinate.
 C: Photograph shows the broken mass.
 D: Following removal of the mass, the passageway is clear.

Mercado, JC, Goldberg SG. Recurrent purulent rhinorrhea in an otherwise healthy woman Ear Nose Throat J. 2004 Jun;83(6):381-2

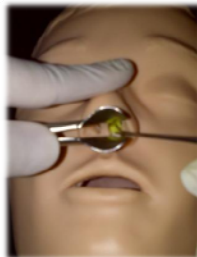Removal Foreign Body (Nose)

Good visualization: headlamp & nasal speculum

Alligator forceps should be used to remove cloth, cotton, or paper

Other hard FB are more easily grasped using bayonet forceps, Kelly clamps, or they may be rolled out by getting behind it using an ear curette, single skin hook, or right angle ear hook

Spray topical anesthetic and decongestant prior to initiating procedure.



Practice mannequins available to practice removal of nasal foreign bodies technique.

Task: Removal Foreign Body Nose
 Indications: Unilateral purulent nasal discharge


1. Explain Procedure. Apply topical anesthetic & decongestant BILATERALLY.
2. Good visualization with use of bright headlight & nasal speculum.
3. Alligator forceps should be used to remove cloth, cotton, or paper. Other hard FB are more easily grasped using bayonet forceps, Kelly clamps, or they may be rolled out by getting behind it using an ear curette, single skin hook, or right angle ear hook
4. Perform flexible fiberoptic endoscopy to check for infection, bleeding and additional foreign bodies.



Control Anterior Epistaxis

Control Anterior Epistaxis

Control anterior epistaxis in office. Apply direct manual pressure for at least 10 minutes

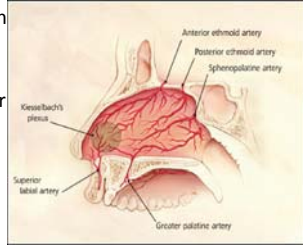


Anterior vs. Posterior Epistaxis

Kiesselbach's Plexus or Little's Area is most common site of anterior nosebleeds.

Woodruff's Plexus is most common site for posterior nose bleeds and may represent a lesion.

Sphenopalatine artery is generally the source of severe posterior nosebleeds.



Etiology of Epistaxis

Local

- Trauma /Nose picking or blowing / surgery
- Dry air / Irritants
- Topical medications (steroids)
- Foreign body
- Tumor

Systemic

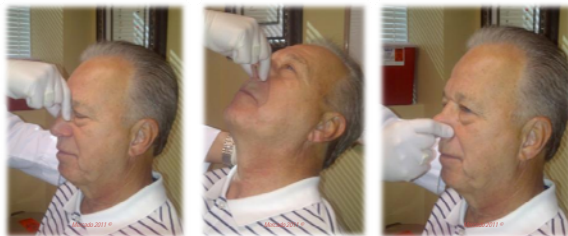- Bleeding disorders
- Hereditary hemorrhagic telangiectasia
- Drugs (anticoagulants)
- Hypertension

Direct Manual Pressure

NO

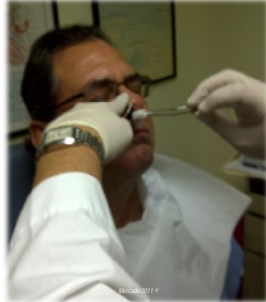NO

YES



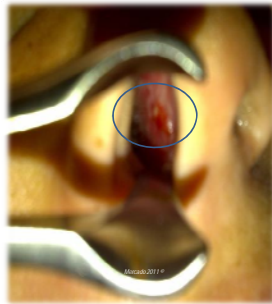Control Anterior Epistaxis

Spray or apply topical anesthetic with decongestant.
Reapply direct manual pressure an additional 10 minutes.



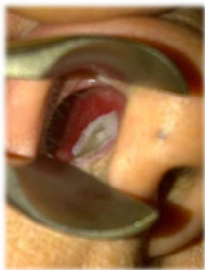Control Anterior Epistaxis

Once bleeding has subsided, identify site of nosebleed.



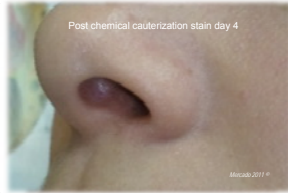Control Anterior Epistaxis

Control bleeding with silver nitrate cauterization. (start from outside in)
Caution bilateral cauterization as may result in septal perforation.



Control Anterior Epistaxis

Lubricate naris with Vaseline or Neosporin ointment.
Let sit for 10-15 minutes to ensure hemostasis is achieved.
Keep cotton in nares for at least 1 hour to prevent staining.
Avoid sneezing, forceful nose blowing, nose picking, etc.
Follow up 2 weeks as re-cauterization may be necessary.



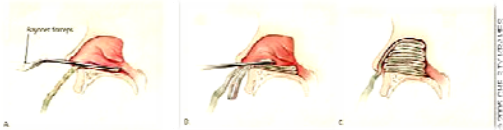Anterior Nasal Packing

- Nasal packing
- Absorbable gelfoam
 - Vaseline gauze
 - Nasal tampon
 - Anterior packing



Anterior Nasal Packing

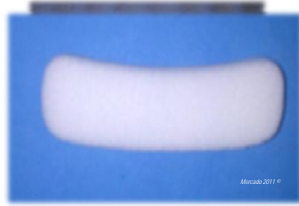- Nasal packing
- Vaseline gauze – is inserted along floor of naris to form a tight seal.



Anterior Nasal Packing

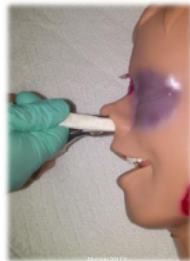Nasal packing

- Nasal tampon – expands in nasal cavity to form a tight seal.
- Do not allow packing to moisten until in position.
- Removal may cause re-bleeding.



Anterior Nasal Tampon

- Insert nasal tampon horizontally.
- Lubricate with Neosporin but DO NOT moisten!
- Secure ties to cheek.

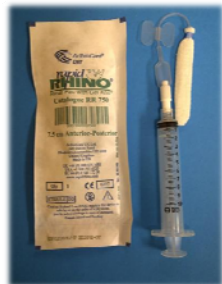

Practice mannequins available to practice anterior nasal packing technique.

Anterior Nasal Packing

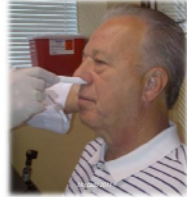
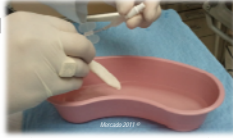Anterior nasal packing

- Easy to insert and remove due to self-lubricating hydrocolloid fabric and ultra-low profile.
- Packing quickly conforms to nasal anatomy and provides gentle and even compression to areas of epistaxis.

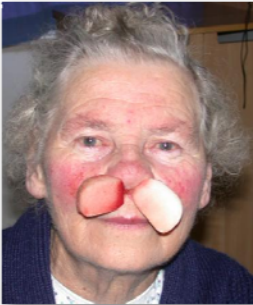

Anterior Nasal Packing

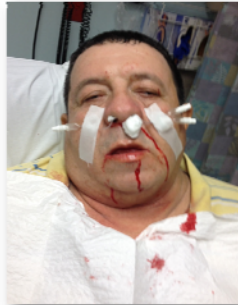- Soak dressing to hydrate Gel Knit hydrocolloid fabric in sterile water for 30 seconds.
- Insert Rapid Rhino horizontally.
- Inflate balloon only with air.
- Tape pilot cuff to side of face.



Which of the following is correct?



A



B

Control Posterior Epistaxis

Anterior vs. Posterior Epistaxis

Kiesselbach's Plexus or Little's Area is most common site of anterior nosebleeds.

Woodruff's Plexus is most common site for posterior nose bleeds and may represent a lesion.

Sphenopalatine artery is generally the source of severe posterior nosebleeds.

Posterior tend to be more difficult to control and may suggest an underlying etiology.

Etiology of Epistaxis

Local

- Trauma (Nose picking or blowing)
- Dry air / Irritants
- Topical medications (steroids)
- Foreign body
- Tumor / polyp
- Surgery

Systemic

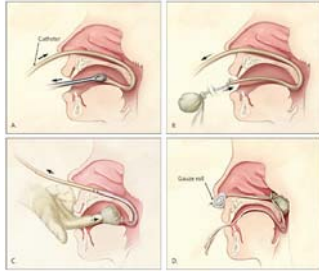
- Hypertension
- Coagulopathies
- Hereditary hemorrhagic telangiectasia
- Drugs (anticoagulants)

Control Posterior Epistaxis

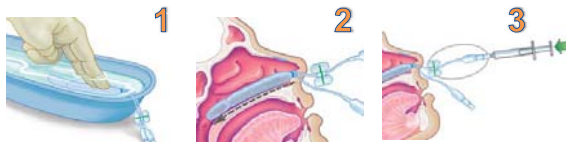- Control Hypertension
- Identify Coagulopathy –Treat with FFP, transfusions, etc
 - PT, PTT, INR
- Coumadin toxicity - Vitamin K
- Posterior Packing
- Endoscopic Cauterization
- Arterial Embolization (Interventional Radiology)

Posterior Nasal Packing

- Topical anesthetic & decongestant
- Posterior nasal packing
 - Foley catheter
 - Double balloon device

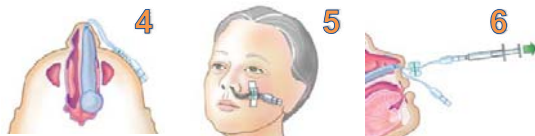

Posterior Packing Epistaxis



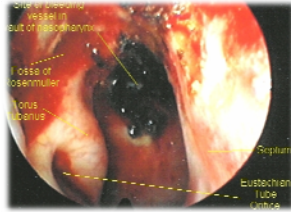
1. Thoroughly soak in sterile water for 30 seconds.
2. Insert Rapid Rhino into the patient's nostril parallel to the septal floor, or following along the superior aspect of the hard palate, until the blue indicator ring is inside the opening of the nostril.
3. Using a 20 cc syringe, slowly inflate the posterior (green stripe) balloon **first** with air only inside the patient's nose.

Posterior Packing Epistaxis



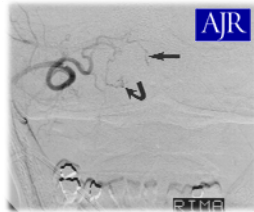
4. Inflate second balloon with air.
5. Allow the patient to sit for 15-20 minutes prior to discharge. Swelling in the nasal anatomy will reduce and the balloons may need to be inflated more to avoid movement of the device. **Don't forget prophylaxis antibiotics!**
6. To remove packing, deflate balloons 24-72 hours later.

Additional Treatments



Endoscopic Cauterization
B. Ghorayeb, MD

<http://www.ghorayeb.com/Epistaxis/Posterior/EndoscopicView.html>

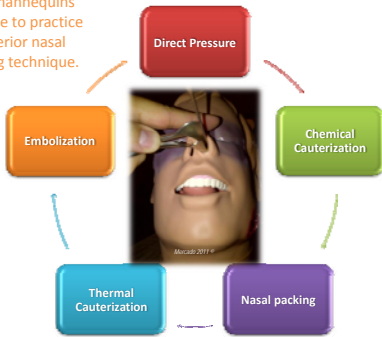


Arterial Embolization
Koh E et al. AJR 2000;174:845-851

<http://www.ajronline.org/content/174/3/845.full>

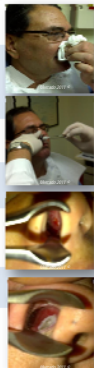
Summary Epistaxis

Practice mannequins available to practice posterior nasal packing technique.



Task: Control Anterior Epistaxis
Indications: Anterior persistent nosebleed in office

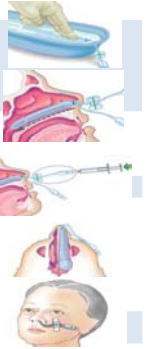
1. Apply direct manual pressure for at least 10 minutes.
2. Spray or apply topical anesthetic with decongestant. Reapply direct manual pressure an additional 10 minutes
3. Once bleeding has subsided, identify site of nosebleed
4. Control bleeding with silver nitrate cauterization. (start from outside in)
5. Lubricate naris with Vaseline or Neosporin ointment. Keep cotton in nares for at least 1 hour to prevent staining.
6. Let sit for 10-15 minutes to ensure hemostasis is achieved.



- Avoid sneezing, forceful nose blowing, nose picking, etc.
- Follow up 2 weeks as re-cauterization may be necessary.

Task: Control Epistaxis
Indications: Persistent anterior or posterior nosebleed despite cauterization


1. Thoroughly soak in sterile water for 30 seconds.
2. Insert nasal pack into the patient's nostril parallel to the septal floor, or following along the superior aspect of the hard palate, until the blue indicator ring is inside the opening of the nostril.
3. Using a 20 cc syringe, slowly inflate the posterior (green stripe) balloon *first* with air only inside the patient's nose.
4. Inflate second balloon with air.
5. Allow the patient to sit for 15-20 minutes prior to discharge. Swelling in the nasal anatomy will reduce and the balloons may need to be inflated more to avoid movement of the device. **Don't forget prophylaxis antibiotics!**
6. To remove packing, deflate balloons 48-72 hours later.



Fine Needle Aspiration

Site Selection

Common sites include thyroid and parotid glands as well as lymph nodes.

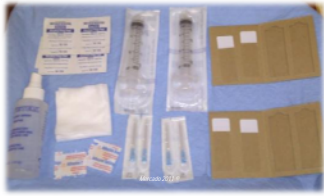

Anesthesia

- For superficial aspirates, clean technique suffices for cleansing of the skin surface.
- Local anesthetic may or may not be used. If more than two or three attempts are anticipated, this is recommended.
- However, be certain not to contaminate the lesion with a large volume of anesthetic.
- Also, make attempts not to directly interfere with the ability to palpate and localize the lesion.
- For deep aspirates, sterile technique is required for cleansing of the skin and local anesthetic is usually required.

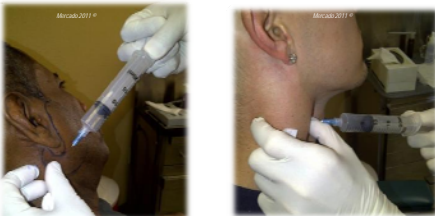
Fine Needle Aspiration

- Use a 3, 5, 10 or 20 mL syringe. Use of a "Syringe Pistol" is optional.
- Needle should be at least 1 1/2 inch or appropriate length and be 22 to 25 gauge.
- Single end label clear glass slides (for preparation of direct smears).
- Fixative to preserve fixed slides (either Cytology spray fixative, Saccomanno fixative or 95% ethyl alcohol in coplin jar).



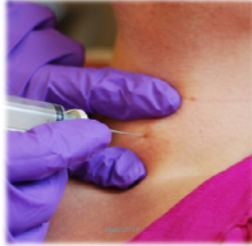Fine Needle Aspiration

Palpate and identify mass or lesion.
Clean topically with alcohol.
Stabilize the mass with non-dominant hand.
Insert needle through the skin with a quick motion.



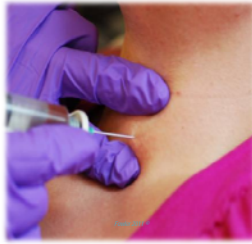Fine Needle Aspiration

- Advance through the subcutaneous tissue into the mass. Aim needle toward the center of small masses but toward the periphery of larger masses as the center may be necrotic.
- A noticeable difference in the consistency of the tissue should be noted when the needle penetrates the mass.
- With the needle in the mass, the needle tip should be moved in short motions initially to loosen cells within the mass.
- Pull back on plunger to create negative pressure.



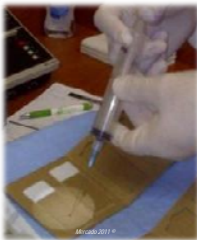Fine Needle Aspiration

- Without releasing pressure, withdraw the needle within the target slightly then reinsert at a slightly different angle.
- Repeat maneuver several times before complete withdrawal. May also perform a corkscrew action before withdrawal.
- If blood or material appears in the hub of the needle, the aspiration should be stopped.
- Release negative pressure before withdrawing the needle, negative pressure must be released to prevent suction of the material into the barrel of the syringe when the needle exits the skin.

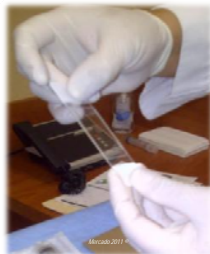

Preparing Slides

Transfer specimen from needle hub to slides.



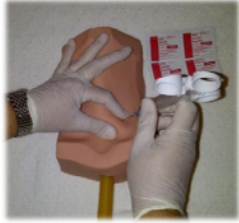Gently and evenly spread specimen between two slides before fixing. Allow to air dry before closing slide holder.



Fine Needle Aspiration

Aspiration techniques vary widely based on personal preference, and specific clinical circumstances.

Goal is to collect adequate cellular material for cytologic evaluation.



Practice mannequins available to palpate and practice technique.

Task: Fine Needle Aspiration

Indications: Obtain histopathologic diagnosis of suspected neoplasms

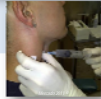
1. Explain Procedure. Prepare supplies

2. Palpate and identify mass or lesion.

3. Clean topically with alcohol.

4. Stabilize the mass with non-dominant hand. Insert needle through the skin with a quick motion.

5. Transfer specimen to slides and either fix or immediately submerge in alcohol.



Peritonsillar Abscess

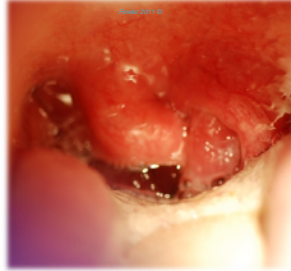Peritonsillar Abscess

History

- Severe Odynophagia
- Dysphagia

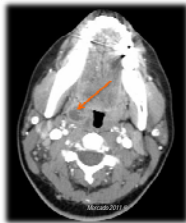
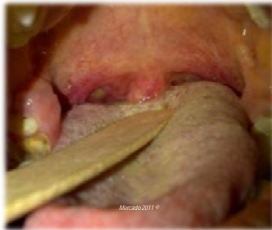Physical

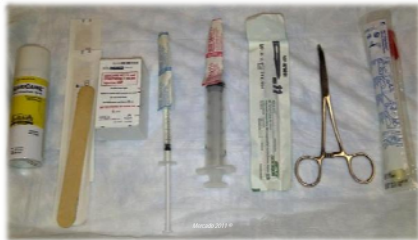- Fever
- Unilateral edema
- Hot Potato Voice
- Elevated white count (CBC)
- CT Scan with contrast



Peritonsillar Abscess

Strong clinical suspicion without obvious physical findings.





Equipment needed

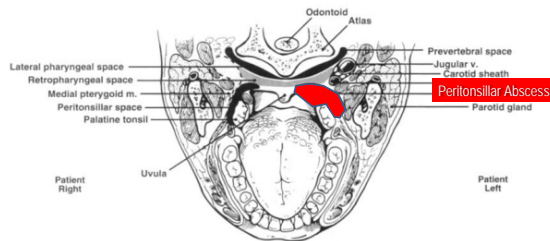
Hurricane spray
Lidocaine w/ epi
Tongue Blade
Scalpel

Headlight
Suction setup
Long tonsil clamp
Culturette

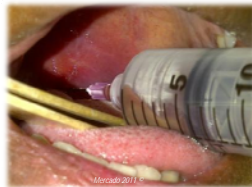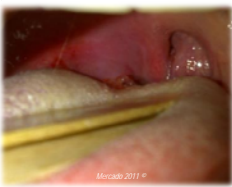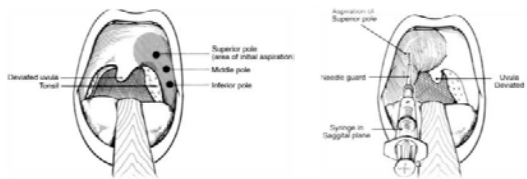
Peritonsillar Abscess

- Management options
 - Needle aspiration
 - Incision and Drainage
 - Quinsy tonsillectomy
- Choice will depend on site and location of abscess. Smaller, deep abscess are sometimes easier to reach with large bore needle.
- Both have similar success rates (Needle Aspiration 90-95% vs. I and D 90-100%)

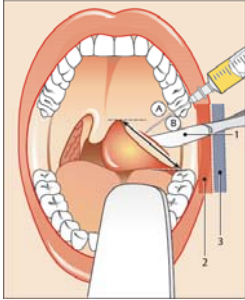
Peritonsillar Abscess




Needle Aspiration




Incision and Drainage



Incision & Drainage with #15 blade



Blunt Dissection with curved hemostat



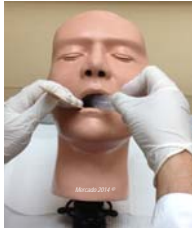
Peritonsillar Abscess

Discharge instruction :
 Penicillin based antibiotics 7-10 days.

Oral prednisone (medrol dose pack).







In-office follow up 2 weeks.

Possible tonsillectomy.









Practice mannequins available to practice drainage of PTA.

Peritonsillar Abscess

<p>New PTA insert simulates bilateral peritonsillar abscess with trismus.</p>  <p>Attendees can practice incision of peritonsillar abscess.</p>	<p>Attendees can practice injection of topical and local anesthetic.</p>  <p>Attendees can practice drainage of peritonsillar abscess using blunt dissection.</p>	<p>Attendees can practice needle aspiration of abscess.</p>  <p>Simulated abscess can then be replaced for additional practice.</p>
		

Practice mannequins available to simulate PTA and practice needle aspiration technique.

Task: Drainage Peritonsillar Abscess
 Indications: Drainage peritonsillar abscess >1cm.

1. Explain Procedure. Prepare supplies and locate landmarks 
2. Apply topical anesthetic, inject local anesthetic. 
3. Insert large bore needle with guard (optional) over area of greatest fluctuance (imaging). 
4. Aspirate pus (release pressure when with drawing). 
5. Perform incision at the point of maximum protrusion, usually between the uvula and the second upper molar tooth. 
6. Perform blunt dissection with curved hemostat. 

Treat with PCN based antibiotics and oral steroids.


Johnson RF, Stewart MG, Wright CG. An evidence-based review of the treatment of peritonsillar abscess. Otolaryngol Head Neck Surg. 2003;128(3):332-343

Auricular Hematoma

Acute auricular hematoma is common after blunt trauma to the side of the head. A network of vessels provides a rich blood supply to the ear, and the ear cartilage receives its nutrients from the overlying perichondrium. Prompt management of hematoma includes drainage and prevention of reaccumulation.


Several articles recommend drainage within 5 days to prevent irreversible cartilage thickening. However, authors have had great results draining up to 10 days provided there is fluctuance.

The mechanism of hematoma drainage has been debated. To date, no randomized controlled trials have addressed this issue.



Auricular Hematoma

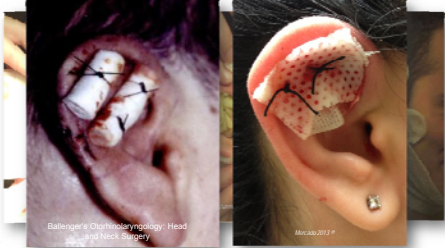
If left untreated, an auricular hematoma can result in complications such as perichondritis, infection, and necrosis. Cauliflower ear may result from long-standing loss of blood supply to the ear cartilage and formation of neocartilage from disrupted perichondrium. The goal of treatment is to completely evacuate subperichondrial blood and to prevent its reaccumulation and associated deformity.



Auricular Hematoma

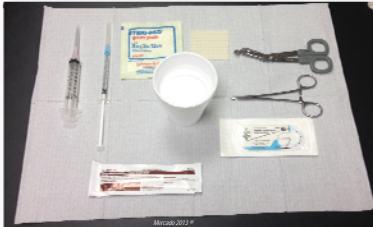
Methods of applying pressure to area of hematoma include

1. compression dressing
2. external splinting



Ballegaert's Otorhinolaryngology - Head and Neck Surgery
March 2012 #

Equipment




March 2012 #

1. Anesthesia	5. Bandage scissors
2. 10cc syringe drain hematoma	6. Betadine prep
3. Aquaplast®	7. Gauze
4. Hot water 160°F	8. 0 silk straight needle (needle driver)

Auricular Hematoma

Prepare 1/16inch thick Aquaplast by making pattern on OPPOSITE ear.

- a) Cut to shape and size of area to compress on anterior surface.
- b) Cut oval or kidney shape for posterior surface.



March 2012 #

Auricular Hematoma

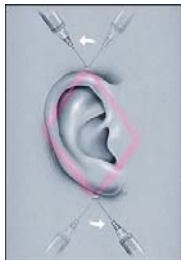
Pearls for working with Aquaplast.

- Make pattern on OPPOSITE ear.
- Fine tune on OPPOSITE ear before working on injured ear.
- Use good bandage scissors
- Cut round smooth edges



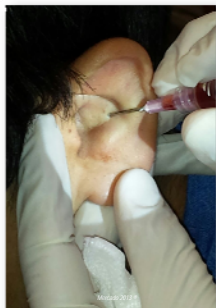Auricular Hematoma

1. Place patient in sitting position with head supported.
2. Inject 1% lidocaine with or without epinephrine RING BLOCK technique.



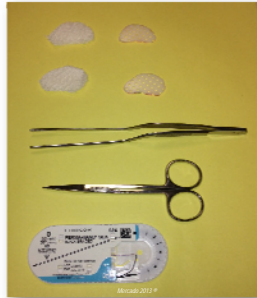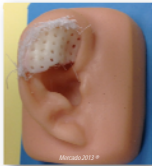Auricular Hematoma

Evacuate hematoma (incision & drainage or 18ga needle aspiration)



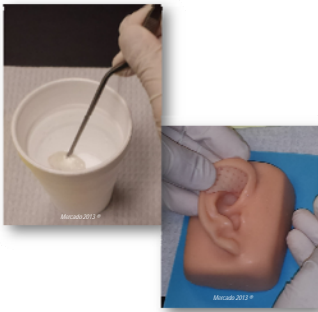
Auricular Hematoma

Prepare non-adherent gauze pad or petroleum gauze the shape of the Aquaplast so they project 1-2 mm BEYOND margins



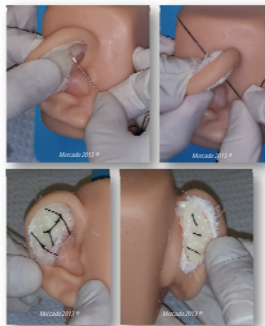
Auricular Hematoma

Immerse Aquaplast in hot water (160F) until it becomes transparent.
Place splint over site (Aquaplast will NOT burn underlying skin) and allow to conform to ear surface as it cools.
Repeat process for posterior splint.



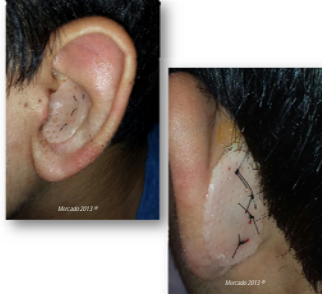Auricular Hematoma

9. After placement of gauze pads between the splints and the skin surface secure with two or three through and through 0 silk on a straight needle to snugly compress splint dressing to hematoma in sandwich fashion.

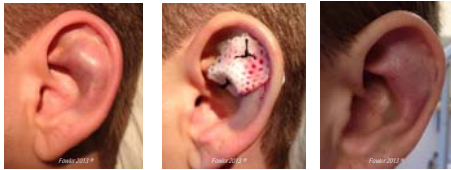


Auricular Hematoma

10. Discharge on oral antibiotics (cephalexin) and follow up 7-10 days for removal of sutures.



References

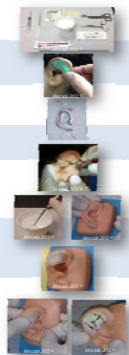

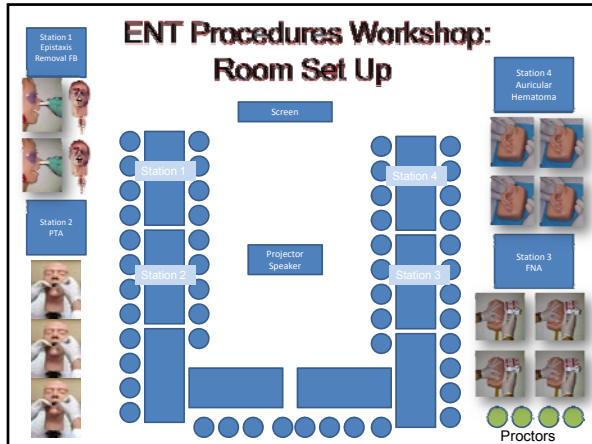
Biedenbach P, Steehler KW, Anon JB. Management of Auricular Hematoma using Aquaplast Pressure Dressing. Operative Tech in Otolaryngology HNS, vol 8, No 2, 1997:114-115.
Mudry A, Pirag W. Auricular hematoma and cauliflower deformation of the ear: from art to medicine. Otol Neurotol. Jan 2009;30(1):116-20
Giles WC, Iverson KC, King JD, Hill FC, Woody EA, Bouknight AL. Incision and drainage followed by mattress suture repair of auricular hematoma. Laryngoscope. Dec 2007;117(12):2097-9.
Greywoode JD, Pribitkin EA, Krein H. Management of auricular hematoma and the cauliflower ear. Facial Plast Surg. Dec 2010;26(6):451-5 v

Task: Drain Auricular Hematoma

Indications: Drainage hematoma within 5-10 days to prevent irreversible cartilage thickening.

1. Explain Procedure. Prepare supplies
2. Prepare 1/16inch thick Aquaplast by making pattern on OPPOSITE ear.
3. Inject anesthesia (ring block).
4. Drain hematoma.
5. Immerse Aquaplast in hot water (160°F) until it becomes transparent. Then mold over site.
6. Prepare non-adherent gauze pad or petroleum gauze the shape of the Aquaplast so they project 1-2 mm BEYOND margins
7. After placement of gauze pads between the splints and the skin surface secure with two or three through and through D silk on a straight needle to snugly compress splint dressing to hematoma in sandwich fashion.





ENT Procedures Workshop Evaluations

Score cards will be used for admission to workshops and attendance.
Credit will only be awarded for completed score cards.

Name	Session 1 2 3 4 5
On scale of 1 through 5 with 5 being most likely	Scale 1-5
1. Were learning objectives met?	
2. Was instruction free of commercial bias?	
3. Was there adequate instruction before practice?	
4. Was there adequate supervision during practice?	
5. Were training aids useful/realistic in learning skill?	
6. How likely are you to perform these skills in future	
7. Did this training improve your skills?	
Comments:	

ENT Procedures Workshop Score Card

Rotate and complete each station.
"Go/No Go" for internal use only.
Completion of workshop is NOT contingent on pass/fail.

Name	Session 1 2 3 4 5
Task	Go No Go
Removal Nasal FB	
Control Anterior Epistaxis	
Control Posterior Epistaxis	
Perform FNA	
Drain PTA	
Drain & splint auricular hematoma	
Comments	
Proctor Name	Proctor Signature
